Quill BARBED SUTURE

Case example:
Use of Quill® barbed suture in laparoscopic ventral and dorsal hiatoplasty

Intraoperative site showing the treatment of a hiatus hernia.

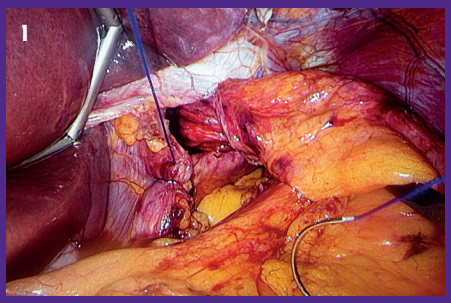

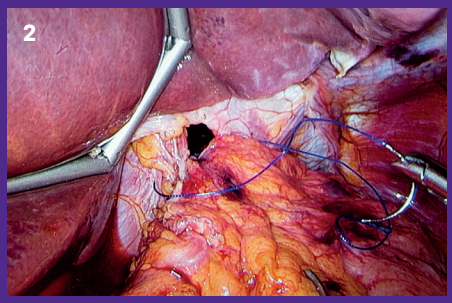

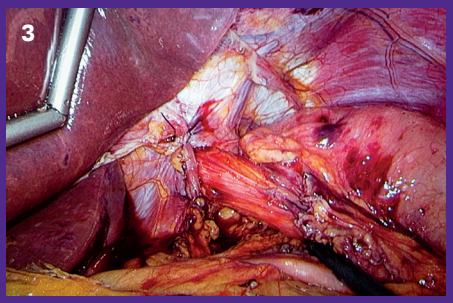

1-2: Continuous suturing of the diaphragmatic crura as dorsal/posterior (1) and ventral/anterior (2) hiatorrhaphy with Quill®.

3: Complete hiatoplasty prior to creation of the dorsal hemifundoplication.

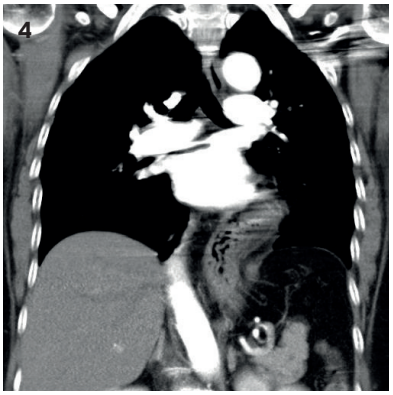

4: Preoperative computer tomography (CT) of the thorax/abdomen in the frontal plane: The image shows that large parts of the stomach have been pushed through the hiatus into the thorax.

Preliminary remarks:

- The most common type of hiatus hernia is an axial hiatus hernia with consecutive gastroesophageal reflux disease (GERD), which is a relative indication for surgery.[1-3]
- Higher-grade hiatus defects, such as a paraesophageal hernia, upside-down stomach (UDS) or enterothorax, are absolute indications for surgery.[3]
- Closing the hernia or narrowing the crura in conjunction with a fundoplication significantly improves the reflux disease.[4]
- The operation is usually performed as a laparoscopy.
- In addition to the risks of intraoperative injury to the oesophagus/stomach, bleeding and compromising the vagus nerve branches, postoperative dysphagia represents a specific major risk.[3]
- A hiatus hernia is closed during reflux surgery by suturing the diaphragmatic crura; for large hernias, a mesh can also be used.[4]
- Each year, around 50 hiatoplasties are performed in the Surgical University Hospital Rostock. Quill®, a self-retaining barbed suture, is regularly used for the procedure. The use of a running stitch makes it ideally suited to this area.

Patient history:

- 72-year-old woman who has suffered symptoms of reflux oesophagitis and dysphagia for several years.
- Nicotine abuse.
- Diagnosed with a hiatus hernia and partial upside-down stomach.
- Laparoscopic repositioning and hiatoplasty with additional fundus cuff indicated.

corzamedical

Quill BARBED SUTURE

Case example:

Use of Quill® barbed suture in laparoscopic ventral and dorsal hiatoplasty.

Intraoperative site showing the treatment of a hiatus hernia.

Surgical procedure:

- Primary intervention as a laparoscopy, preferably with four trocars.
- Retract the left hepatic lobe using a multi-way clamp.
- Incise the flaccid portion of the lesser omentum, exposing the right crus of the diaphragm.
- Separate the short gastric vessels around the fundus along the greater curvature, detaching the superior pole of the spleen and exposing the left crus of the diaphragm.
- Continue in a circular fashion, exposing the gastroesophageal junction while protecting the vagus nerve branches.
- Measure the defect.
- Check the fundus cuff.
- Perform the hiatoplasty using Quill® 1 (VLO-1005: USP 1 (4.0 Metric), Undyed, SH-1 (1/2 Circle, 22 mm), 15 cm) with a running suture along the diaphragmatic crura.
- Secure the hiatoplasty with anterior hemifundoplication (Toupet).

Conclusion:

- The suture and needle were simple to handle.
- The use of a self-retaining suture makes the procedure much easier and considerably reduced surgery time by about 25 minutes, compared to a traditional suture.
- The use of non-absorbable sutures ensures the long-term outcome of the operation.
- Quill® enables the tension forces to be distributed in a continuous technique that could be gentle on the tissue.
- Quill® can be recommended for routine use.

Corza.com 1.877.991.1110 Service@corza.com
Quill® is available through distribution or direct. For procedural videos, visit youtube.com/CorzaMedical

Reference: According to information and estimates from Dr M. Philipp, MD, Head of Minimally Invasive, Hernia, Endocrine and Bariatric Surgery, Surgical University Hospital Rostock.

1. Diermann J. [Internet]. Pschyrembel online. [cited 2023Jan27]. Available from: https://www.pschyrembel.de/Hiatushernie/K09T8; 2. Koop H, et al. S2k guideline: gastroesophageal reflux disease guided by the German Society of Gastroenterology: AWMF register no. 021-013. Z Gastroenterol. 2014 Nov;52(11):1299-346; 3. Schumpelick V et al. Allgemein- und Viszeralchirurgie up2date 2020; 14(03): 254-257; 4. Wolf S et al. Der Chirurg 2021; 92:377.

corza.com

Corza Medical, 247 Station Drive, Suite NE1, Westwood, MA 02090, U.S.A.

COR 408 R0 01/23

corzamedical